

OTOPLASTY FOR PROMINENT EARS IN CHILDREN. THE TECHNIQUE ADOPTED IN THE PORTMANN INSTITUTE H. Abou Mayaleh, H. S. Khalil, D. Portmann, M. Négrevergne ¹

INTRODUCTION

Protruding ears (lop ears, bat ears) are the most common auricular deformities for which patients seek consultation. These deformities belong to the first degree dysplasias and result from an overdeveloped concha, an underdeveloped anthelix or a prominent lobule. Otoplastic technique to correct these malformations are based on such surgical principle such as suturing, incision, excision, scoring and burring of the auricular cartilage (1). A plethora of surgical techniques have been described in the literature (2, 3, 4).

INDICATION

Prominent ears typically do not affect a child's self-image until the child is older than 7 or 8 years. Otoplasty is best performed when the child requests a treatment for the deformity. We describe the technique adopted in the Portmann Institute for treating children with this condition.

Advantages

- ⇒ A rapid technique,
- ⇒ Maintenance of the natural contours of the auricle,
- ⇒ Minimal exposure and dissection of the cartilage thus minimising the risk of cartilage infection.

Disadvantages

- ⇒ Sometimes, there is some obliteration of the postauricular groove.

Complications

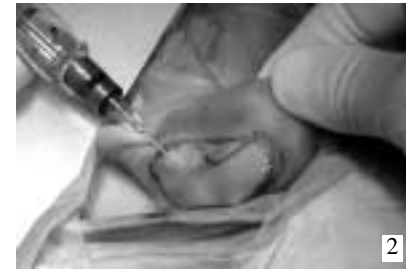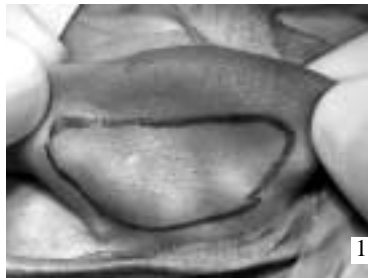Complications of otoplasty include under correction of the protrusion, chondritis, hypertrophic scar and late recurrence (5).

Summary

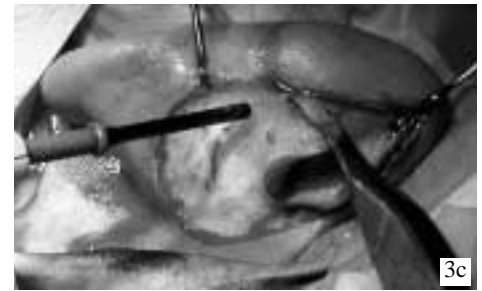
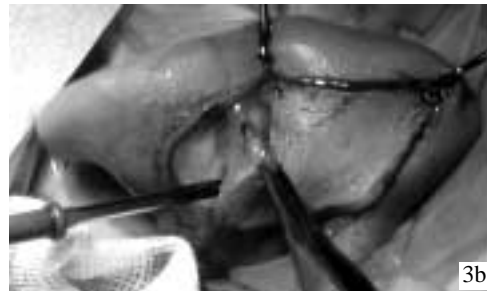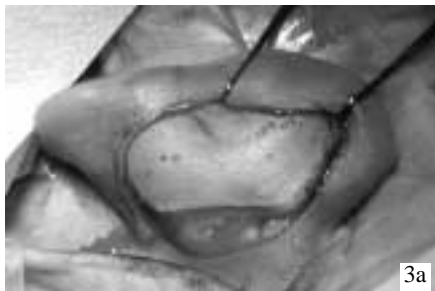
The Otoplasty technique adopted in the Portmann Institute is a simple rapid technique that maintains the natural contours of the auricle with minimal risk of infection. The technique involves excision of a large ellipse of skin from the mastoid surface of the auricle and reflection of remaining skin to the edge of the helix. The subcutaneous and muscular tissues on the mastoid bone are excised and the mastoid surface of the auricular cartilage scored with monopolar diathermy. After haemostasis, the wound is closed using continuous long-term absorbable sutures. A dressing and bandage are applied and the child is monitored for 10 days. A head bandage is applied at night for one month with use of a sun-screen cream on the scar at daytime.

SURGICAL TECHNIQUE

1. General anaesthesia is administered with endotracheal intubation.
2. Positioning: The patient is positioned in the supine position and both ears are prepared using povidone iodine (Betadine) solution.
3. The skin incision on the mastoid surface of the auricle is outlined using a sterile pen marker (Figure 1).



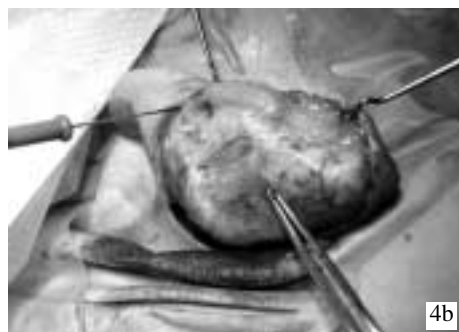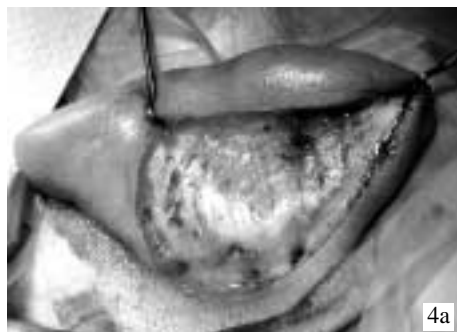4. The outlined area is infiltrated with xylocaine 0.5%, adrenaline 1/200.000 (Figure 2).



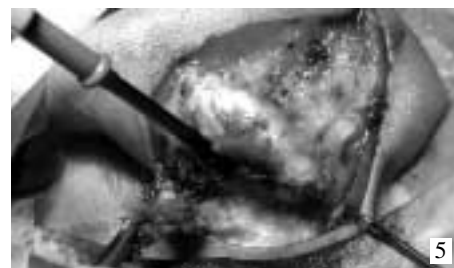5. The area of outlined skin is excised completely down to the level of the perichondrium using monopolar cutting diathermy (Figure 3a/b/c).

1. Institut Georges Portmann, 114 avenue d'Arès, 33074 Bordeaux Cedex, France. Email: orl.bordeaux@wanadoo.fr
(H. S. Khalil - Email: KHALILHSA@aol.com)

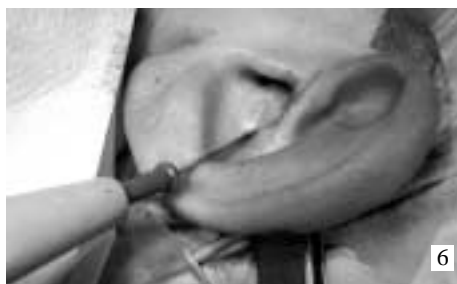6. The remaining skin on the mastoid surface of the auricle is elevated anteriorly up to the level of the margin of the helix and posteriorly to the level of the mastoid bone (Figure 4a/b).



7. The subcutaneous and muscular layer over the mastoid bone is excised with preservation of the periosteum again using monopolar diathermy (Figure 5).



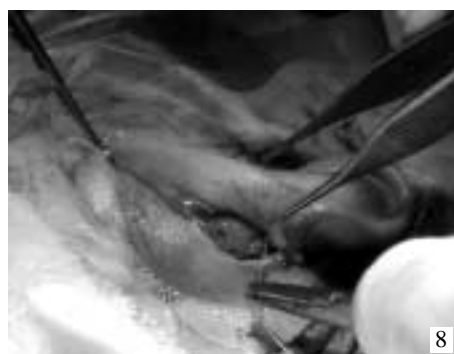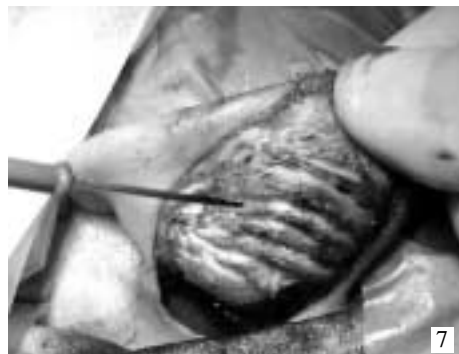8. The patency of the external auditory meatus is checked after positioning of the auricle in its new position (Figure 6). A conchoplasty is performed if the meatus becomes stenosed on backward positioning of the auricle.



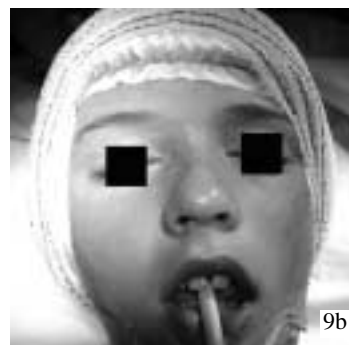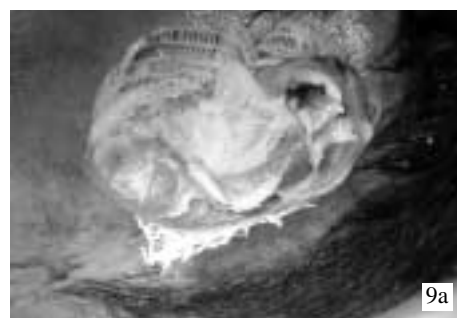9. The mastoid surface of the auricular cartilage is scored using monopolar cutting diathermy in lines parallel to the line of the antihelix (Figure 7).

10. Meticulous haemostasis is performed to avoid a postoperative haematoma.

11. The wound is closed using 4/0 continuous monocryl sutures (the wound closure should be performed using long-term absorbable sutures) (Figure 8).



12. The ear is dressed with Madecassol 1% cream (hydrocotyle). Tulle gras is applied to the mastoid surface of the ear. A gauze dressing is applied followed by a head bandage which is left insitu for 10 days (Figure 9a/b). During the postoperative period, the child is monitored for pain and daily temperature readings.

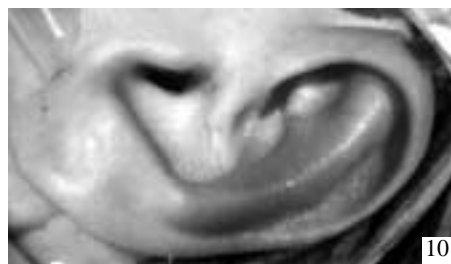

13. After removal of the bandage, the child is given a head band to wear on the ears at night only for one month (Figure 10).

14. A sunscreen cream is applied over the wound scar to avoid the risk of keloid formation particularly in children of a black race.

CONCLUSION

The otoplasty technique adopted in the Portmann institute is a rapid technique that is easy to learn. It maintains the natural contour of the auricle and avoids the 'sharp edge' deformity that sometimes results from cartilage splitting surgery. In our hands, this technique gives consistently good results with minimal complications.



REFERENCES

1. HEPPT W, TRAUTMANN Y. Otoplastic techniques for the correction of protruding ears. HNO, 1999;47(8):688-94.
2. MUSTARDE JC. The correction of prominent ears using simple mattress sutures. BR J PLAST SURG 1963;16:170-176.
3. FURNAS DW. Correction of prominent ears with multiple sutures. CLIN PLAST SURG 1978;5(3):491-495.
4. WRIGHT WK. Otoplasty goals and principles. ARCH OTOLARYNGOL 1970;92(6):568-572.
5. SCLAFANI A. Otoplasty. www.emedicine.com/ent/COSMETIC_SURGERY.htm